

## OSTEOAMP Case Report

**LATERAL LUMBAR INTERBODY FUSION****Dr. John O'Toole**

Associate Professor of Neurosurgery

Rush University Medical Center

1725 W Harrison Street, Suite 855, Chicago, IL 60612

**Patient****Presented with radiculopathy and lower back pain****Procedure****Lateral lumbar interbody stabilization and fusion at L4-5****Outcome****12-month x-ray confirms fusion**

OSTEOAMP IS A UNIQUELY PROCESSED ALLOGRAFT THAT MAINTAINS AND PRESERVES HIGH LEVELS OF A WIDE ARRAY OF NATURAL GROWTH FACTORS FOUND IN BONE AND BONE MARROW.<sup>1-3</sup>

**Patient**

A 50-year-old female presented to the clinic with bilateral L4 and L5 radiculopathy and lower back pain. The patient was diagnosed with L4-5 spondylolisthesis and bilateral foraminal stenosis (**Figures 1 and 2**). The patient was obese, but otherwise healthy. The patient had undergone 12 weeks of physiotherapy and had received epidural steroid injections. Her symptoms did not improve with conservative management and surgical intervention was indicated.

**Procedure**

The objective of surgery was to perform a lateral lumbar interbody fusion at L4-5 using a PEEK cage and a percutaneous pedicle screw construct for fixation. The procedure was augmented with an extra-large OSTEOAMP sponge, rehydrated with 5 cc of autologous bone marrow aspirate that was harvested from the iliac crest. No complications of surgery were reported.

**Outcome**

The patient had an excellent clinical outcome with complete resolution of radiculopathy and back pain. Dynamic, standing x-rays, taken at 12-months post-operation, showed new bone growth in the L4-5 interbody space (**Figures 3 and 4**). Dynamic, standing flexion and extension x-rays showed no motion at L4-L5 (**Figure 5 and 6**). Pedicle screw fixation was intact. Bone fusion was achieved by 12-months post-operation and the patient was symptom-free.

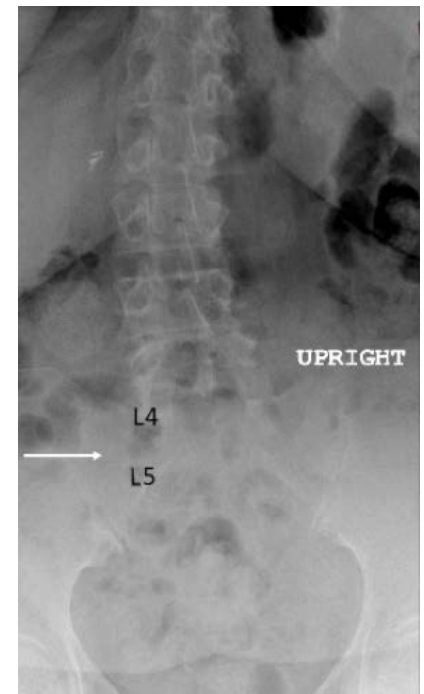


Figure 1: Pre-operative anteroposterior lumbar spine x-ray at L4-5. The arrow indicates narrowing of the disc space between L4 and L5.

## Pre-operative

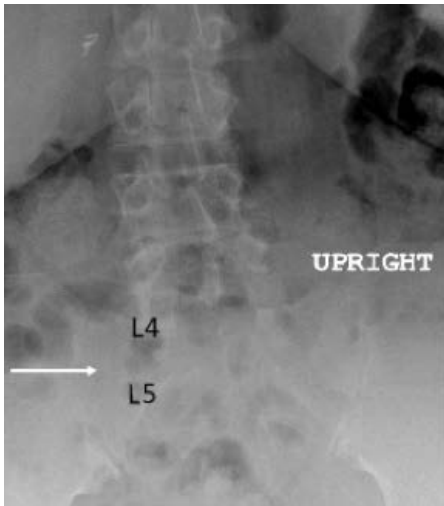


Figure 1: Pre-operative anteroposterior lumbar spine x-ray at L4-5. The arrow indicates narrowing of the disc space between L4 and L5.

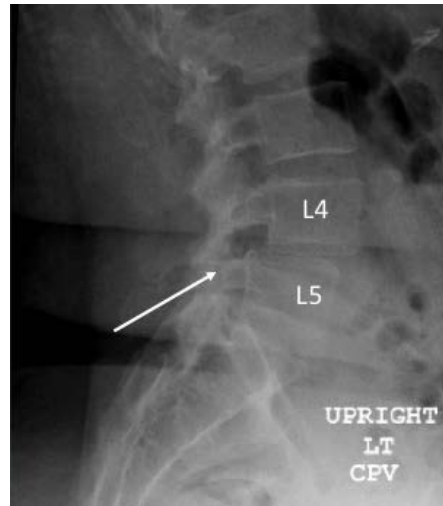
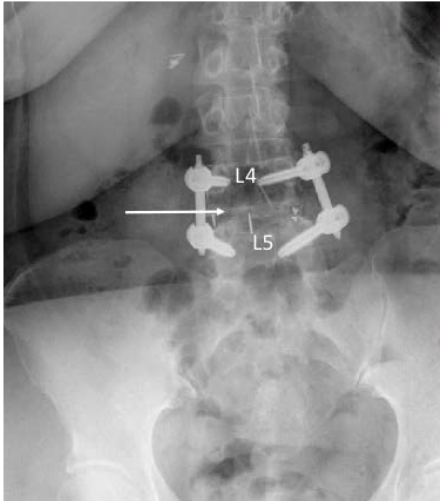
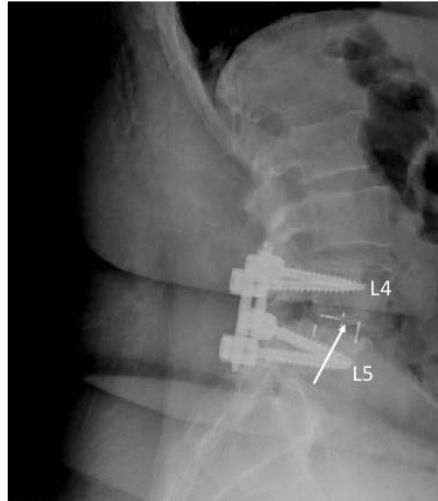


Figure 2: Pre-operative lateral lumbar spine x-ray at L4-5. The vertebral body of L4 has moved posteriorly over L5, resulting in decreased disc space at L4-5 and foraminal stenosis (indicated by the arrow).

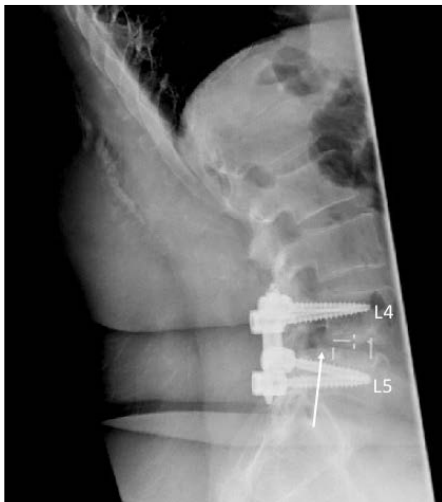## 12-month post-operative



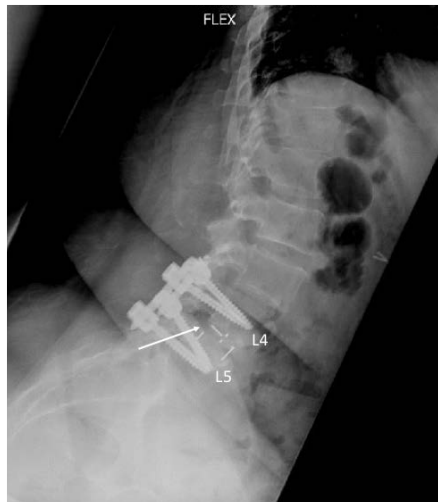**Figure 3:** 12-month post-operative dynamic, standing anteroposterior lumbar spine x-ray at L4-5. The residual PEEK cage is identified by the tantalum markers at L4-5. Posterior fixation is intact with no loosening of the screws. Bone fusion at L4-5 is indicated by the white arrow. The new bone growth is observed within and around the cage between L4 and L5.



**Figure 4:** 12-month post-operative dynamic, standing left lateral lumbar spine x-ray at L4-5. The residual PEEK cage is identified by the tantalum markers at L4-5. Resolution of L4-5 spondylolisthesis is observed with a minor step remaining at the L4-5 junction. Resolution of foraminal stenosis is observed. Bone fusion, as evidenced by new bone growth within and around the cage at L4-5, is indicated by the arrow.



**Figure 5:** 12-month post-operative left lateral lumbar spine x-ray in extension. The arrow indicates the trace spondylolisthesis at L4-5.



**Figure 6:** 12-month post-operative left lateral lumbar spine x-ray in flexion. No movement of the vertebral bodies is observed between the flexion and extension views. The arrow indicates the trace spondylolisthesis at L4-5.

## About OSTEOAMP

OSTEOAMP, an allogeneic bone graft, was developed to provide an alternative to autograft harvested from the iliac crest - the “gold standard” bone graft. However, autograft harvesting is associated with donor site morbidity and is limited in its use by tissue availability.<sup>4</sup> Furthermore, harvesting from the iliac crest increases the overall operating time. Therefore, using an alternative allogeneic bone graft for bone fusion may be preferable.

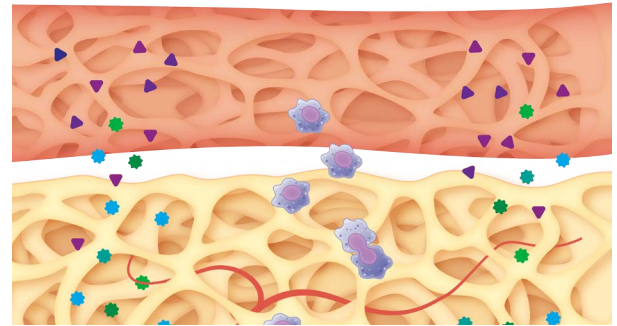
OSTEOAMP is unique as the method of processing the bone graft allows for retention of high levels of naturally occurring growth factors.<sup>1-3</sup> Unlike traditional allografts that are typically processed by washing away the bone marrow, and with that the milieu of growth factors that support bone healing, the OSTEOAMP process uses the bone, including bone marrow, from a single donor. OSTEOAMP contains bone morphogenetic proteins (BMP-2 and BMP-7), transforming growth factor  $\beta$ 1 (TGF- $\beta$ 1) and acidic fibroblast growth factor (aFGF), amongst others.<sup>2</sup> These critical growth factors are known to influence bone formation: BMPs are involved in the regulation of bone formation and induce the differentiation of mesenchymal stem cells into osteoblasts; TGF- $\beta$ 1 enhances proliferation of mesenchymal stem cells and induces the production of extracellular proteins such as collagen, proteoglycans, osteopontin, osteonectin, and alkaline phosphatase; and aFGF helps to increase cell proliferation and enhances cartilage formation.<sup>5</sup> OSTEOAMP is available in three different formats: granules, putty, and compressible sponges, thus enabling augmented bone grafting at various locations.

Several clinical studies with large numbers of patients have reported that OSTEOAMP is a safe and clinically effective bone graft substitute for spine fusion.<sup>6-8</sup> Yeung et al. (2014), a retrospective study, reported a total of 488 different OSTEOAMP allografts from 114 donors that were used in 119 cervical and 166 lumbar procedures without complications.<sup>6</sup> Donor age, gender or tissue intervariability were not clinically relevant to time to fusion. Cervical fusion rates were reported as 83.2% at 6 months, 98.3% at 12 months and 100% at 18 months. Lumbar fusion rates were reported as 68.1% at 6 months, 98.2% at 12 months and 99.4% at 18 months. Another study with 321 patients undergoing lumbar interbody fusion reported that OSTEOAMP led to solid bone fusion in a shorter period of time (~40% less time) with fewer complications and a lower cost per level than rhBMP-2.<sup>8</sup> Thus, the clinical evidence supports the use of OSTEOAMP, both clinically and economically.

John O'Toole is a paid consultant of Bioventus LLC and received compensation from Bioventus LLC related to this article.

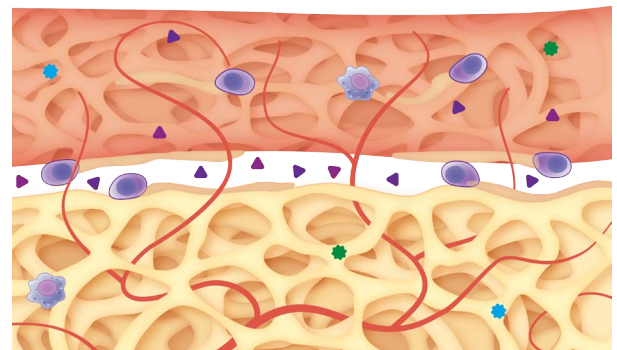
### References

1. Data on file. RPT-000327 Report on Growth Factor Concentrations in Bone and Bone Marrow Aspirate, December 3, 2010, Advanced Biologics, LLC. Data from a single lot of OSTEOAMP sponge product.
2. High levels relative to those reported in published literature for other allografts.
3. Bae H, Zhao L, Zhu D, Kanim L, Wang J, Delamarter R. Variability Across Ten Production Lots of a Single Demineralized Bone Matrix Product. *JBJS*. 2010;92:427-435.
4. Park JJ, Hershman SH, Kim YH. Updates in the Use of Bone Grafts in the Lumbar Spine. *Bulletin of the Hospital for Joint Diseases*. 2013;71(1):39-48.
5. Dimitriou R, Tsiridis E, Giannoudis PV. Current Concepts of Molecular Aspects of Bone Healing. *Injury, Int. J. Care Injured*. 2005; 36:1392-1404.
6. Yeung C, Field J, Roh J. Clinical Validation of Allogeneic Morphogenetic Protein: Donor Intersubject Variability, Terminal Irradiation and Age of Product is not Clinically Relevant. *J Spine*. 2014;3:173.
7. Field J, Yeung C, Roh J. Clinical Evaluation of Allogeneic Growth Factor in Cervical Spine Fusion. *J Spine* 2014;3:158.
8. Roh JS, Yeung CA, Field JS, McClellan RT. Allogeneic morphogenetic protein vs. recombinant human bone morphogenetic protein-2 in lumbar interbody fusion procedures: a radiographic and economic analysis. *J Orthop Surg Res*. 2013;8:49.
9. Data on file. TR-1005 Report on Growth Factor Concentrations in Sponges, Granules and Putty, July 5, 2011, Advanced Biologics, LLC.



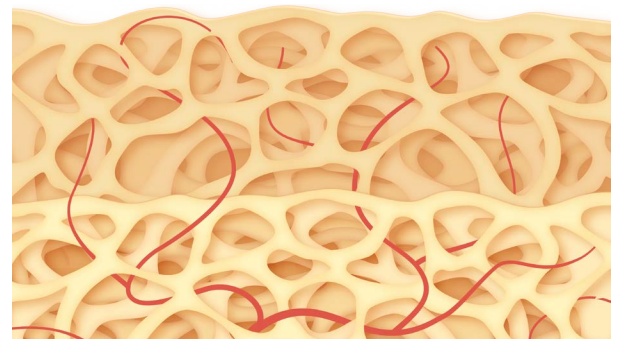
### Step 1

OSTEOAMP, an osteoconductive, osteoinductive, and angiogenic bone graft substitute, is placed at the fusion site.<sup>9</sup> Cells are attracted to the site of injury in response to cytokines and endogenous growth factors in the bone healing environment.



### Step 2

The endogenous osteoinductive and angiogenic growth factors in OSTEOAMP contribute to the bone healing process. Osteoinductive growth factors, such as BMPs, are known to promote cellular recruitment, proliferation and differentiation of bone cells, which promotes bone formation.<sup>5</sup> Angiogenic growth factors initiate development of new vessels. Osteoblasts lay down new osteoid matrix.



### Step 3

OSTEOAMP is incorporated into the site of bone healing. Mineralization of the osteoid matrix occurs, creating solid fusion. This is followed by bone re-modelling where OSTEOAMP is replaced by host bone.

