

## OSTEOAMP Case Report

**POSTEROLATERAL LUMBAR FUSION****Dr. Howard An**

The Morton International Professor, Director of Spine Surgery and Spine Fellowship  
Department of Orthopedic Surgery, Rush University Medical Center  
161 West Harrison Street, Suite 300, Chicago, IL 60612

**Patient**

Presented with chronic lower back and bilateral leg pain

**Procedure**

Laminectomy at L4-5 and L5-S1, discectomy at L4-5 and foraminotomy at right L5-S1 with posterolateral fusion

**Outcome**

CT after 12 months confirms fusion

OSTEOAMP IS A UNIQUELY PROCESSED ALLOGRAFT THAT MAINTAINS AND PRESERVES HIGH LEVELS OF A WIDE ARRAY OF NATURAL GROWTH FACTORS FOUND IN BONE AND BONE MARROW.<sup>1-3</sup>

**Patient**

A 56-year-old male presented to the clinic with chronic lower back pain and bilateral leg pain. He was diagnosed with degenerative disc disease and herniated nucleus pulposus at L4-5 (**Figure 1**), and foraminal stenosis at right L5-S1 (**Figures 2, 3 and 4**). His symptoms had not improved with conservative management and surgical intervention was indicated.

**Procedure**

The objective of the surgery was to perform a laminectomy at L4-5 and L5-S1, a discectomy at left L4-5, and a foraminotomy at right L5-S1. These procedures were followed by posterolateral fusion, augmented with local bone (20 cc) and OSTEOAMP (30 cc granules). Pedicle screws and rods, inserted at L4-S1, were used for fixation. No complications were reported.

**Outcome**

Radiographic assessment at 2-weeks post-operation showed intact pedicle screws and rods (**Figures 5 and 6**). At 10-months post-operation, x-rays showed bone formation inferior to and lateral to the rods, with intact instrumentation, no loosening of instrumentation, and absence of a halo sign (**Figures 7 and 8**). A CT scan at 12-months post-operation showed formation of bone inferior to the rod with no loosening of screws (**Figures 9 and 10**). Bone fusion was achieved by 12-months post-operation (**Figure 11**) and the patient was symptom-free.

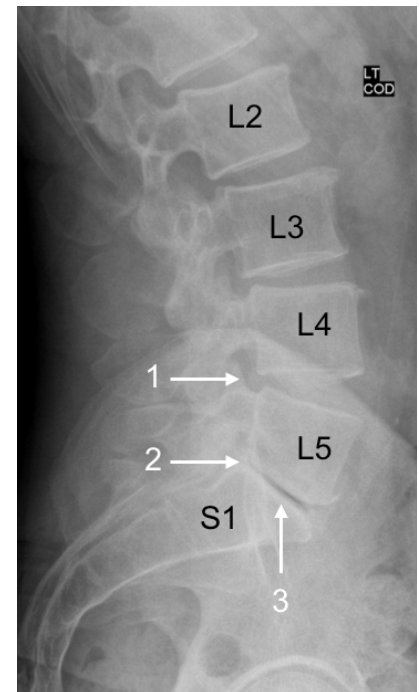
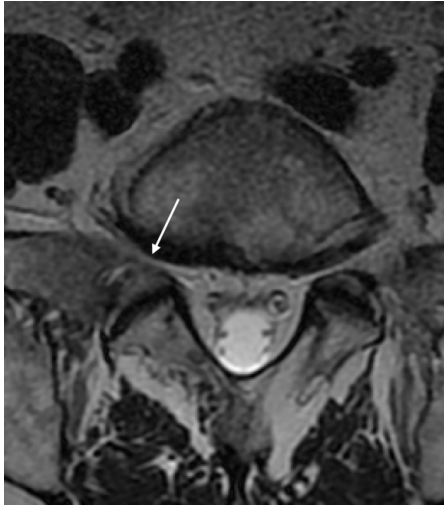
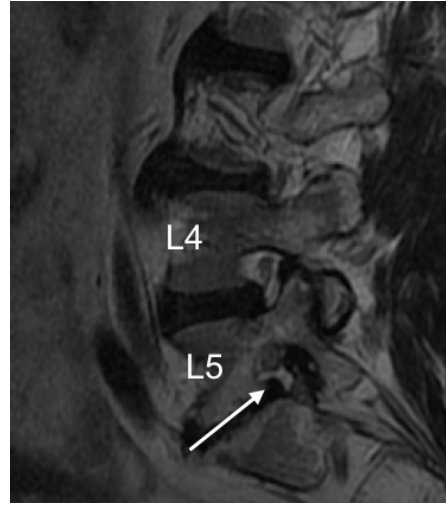


Figure 1: Pre-operative lumbar spine x-ray of the patient. Note the posterior narrowing of the disc at L4-L5 (arrow 1), L5-S1 foraminal stenosis (arrow 2) and narrowed disc space at L5-S1 (arrow 3).

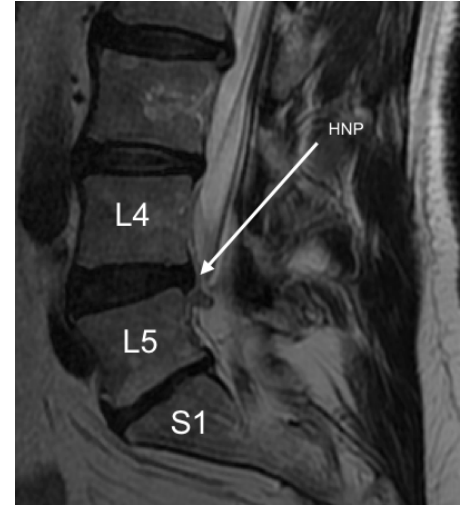
## Pre-operative



**Figure 2:** Pre-operative axial lumbar spine MRI at L5. Note the right foraminal stenosis.

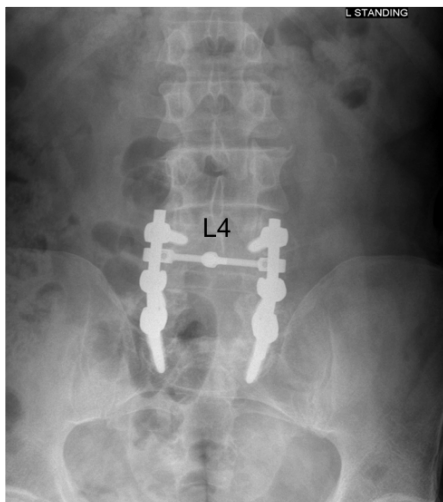


**Figure 3:** Pre-operative, T2-weighted, sagittal lumbar spine MRI, indicating degenerative disc disease at L4-5 and L5-S1 (arrow).

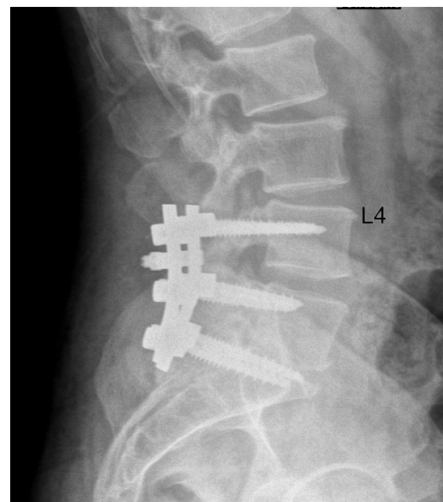


**Figure 4:** Pre-operative, T2-weighted, sagittal lumbar spine MRI, indicating degenerative disc disease at L4-5 and L5-S1, and herniated nucleus pulposus (HNP) at L4-L5. The extruded L4-L5 disc is indicated by an arrow.

## 2 weeks post-operation

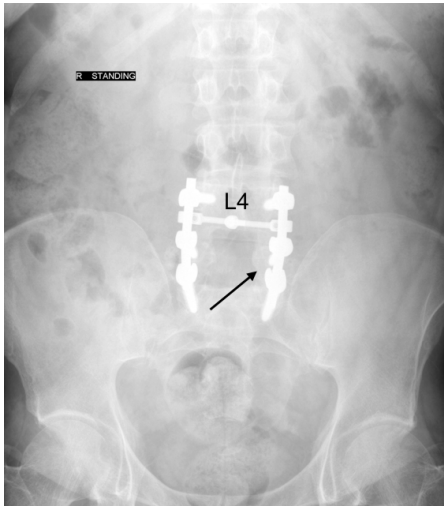


**Figure 5:** 2-week post-operative, standing, anteroposterior lumbar spine x-ray showing intact pedicle screws and rods at L4-S1.

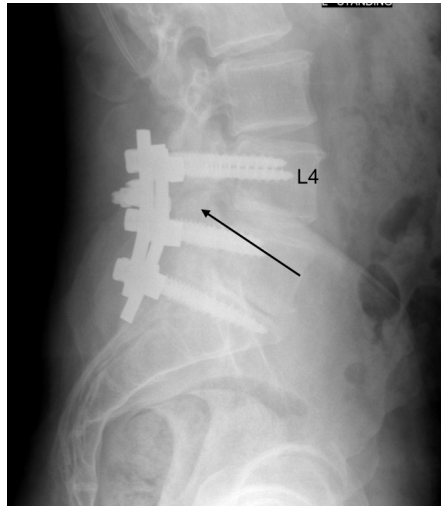


**Figure 6:** 2-week post-operative, standing, left lateral lumbar spine x-ray showing intact pedicle screws and rods at L4-S1.

10 months post-operation

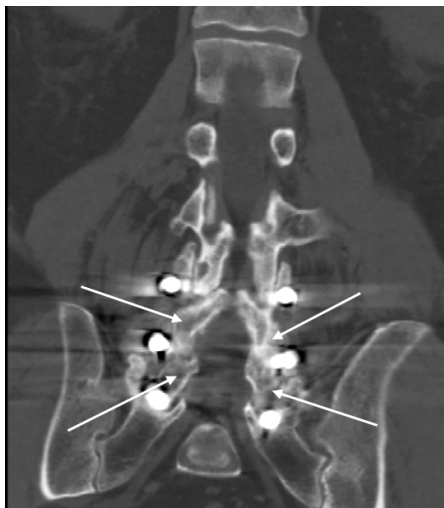

**Figure 7:** 10-month post-operative, standing, anteroposterior lumbar spine x-ray. Note intact instrumentation without any loosening of the screws and absence of halo sign. The arrow indicates new bone formation lateral to the rods.

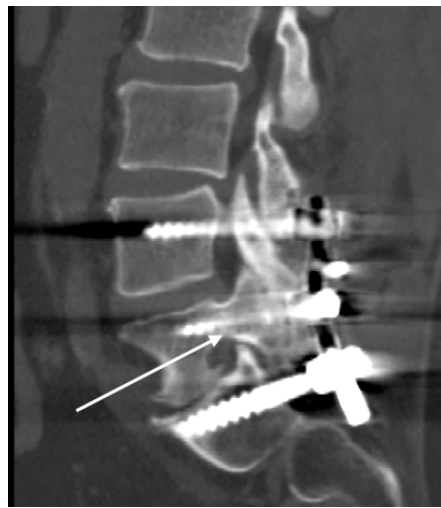


**Figure 8:** 10-month post-operative, standing, left lateral lumbar spine x-ray. The arrow indicates new bone formation inferior to the rods.

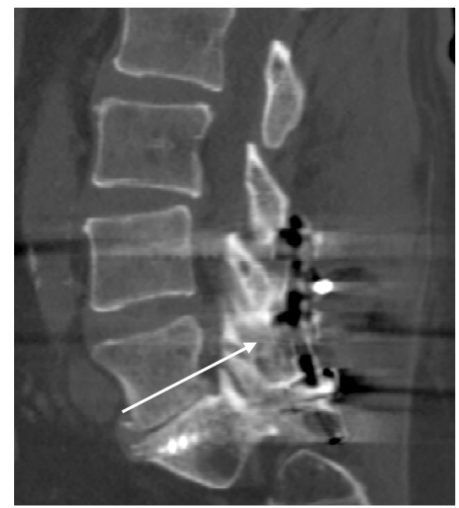12 months post-operation



**Figure 9:** 12-month post-operative coronal lumbar CT scan. The arrows indicate the contiguous bone between the pars and facet joints.



**Figure 10:** 12-month post-operative sagittal lumbar CT scan. There is no loosening or halo around the screws.



**Figure 11:** 12-month post-operative sagittal lumbar CT scan. Bone fusion is indicated by the arrow.

## About OSTEOAMP

OSTEOAMP, an allogeneic bone graft, was developed to provide an alternative to autograft harvested from the iliac crest - the “gold standard” bone graft. However, autograft harvesting is associated with donor site morbidity and is limited in its use by tissue availability.<sup>4</sup> Furthermore, harvesting from the iliac crest increases the overall operating time. Therefore, using an alternative allogeneic bone graft for bone fusion may be preferable.

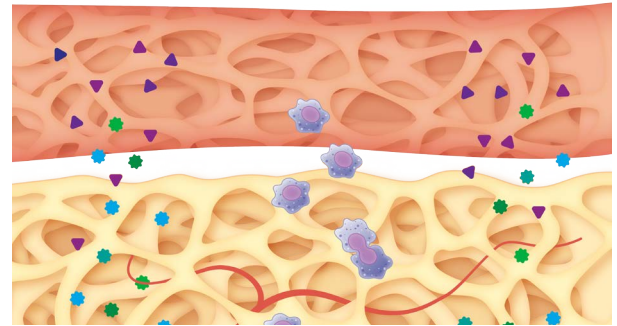
OSTEOAMP is unique as the method of processing the bone graft allows for retention of high levels of naturally occurring growth factors.<sup>1-3</sup> Unlike traditional allografts that are typically processed by washing away the bone marrow, and with that the milieu of growth factors that support bone healing, the OSTEOAMP process uses the bone, including bone marrow, from a single donor. OSTEOAMP contains bone morphogenetic proteins (BMP-2 and BMP-7), transforming growth factor  $\beta$ 1 (TGF- $\beta$ 1) and acidic fibroblast growth factor (aFGF), amongst others.<sup>2</sup> These critical growth factors are known to influence bone formation: BMPs are involved in the regulation of bone formation and induce the differentiation of mesenchymal stem cells into osteoblasts; TGF- $\beta$ 1 enhances proliferation of mesenchymal stem cells and induces the production of extracellular proteins such as collagen, proteoglycans, osteopontin, osteonectin, and alkaline phosphatase; and aFGF helps to increase cell proliferation and enhances cartilage formation.<sup>5</sup> OSTEOAMP is available in three different formats: granules, putty, and compressible sponges, thus enabling augmented bone grafting at various locations.

Several clinical studies with large numbers of patients have reported that OSTEOAMP is a safe and clinically effective bone graft substitute for spine fusion.<sup>6-8</sup> Yeung et al. (2014), a retrospective study, reported a total of 488 different OSTEOAMP allografts from 114 donors that were used in 119 cervical and 166 lumbar procedures without complications.<sup>6</sup> Donor age, gender or tissue intervariability were not clinically relevant to time to fusion. Cervical fusion rates were reported as 83.2% at 6 months, 98.3% at 12 months and 100% at 18 months. Lumbar fusion rates were reported as 68.1% at 6 months, 98.2% at 12 months and 99.4% at 18 months. Another study with 321 patients undergoing lumbar interbody fusion reported that OSTEOAMP led to solid bone fusion in a shorter period of time (~40% less time) with fewer complications and a lower cost per level than rhBMP-2.<sup>8</sup> Thus, the clinical evidence supports the use of OSTEOAMP, both clinically and economically.

Howard An is a paid consultant of Bioventus LLC and received compensation from Bioventus LLC related to this article.

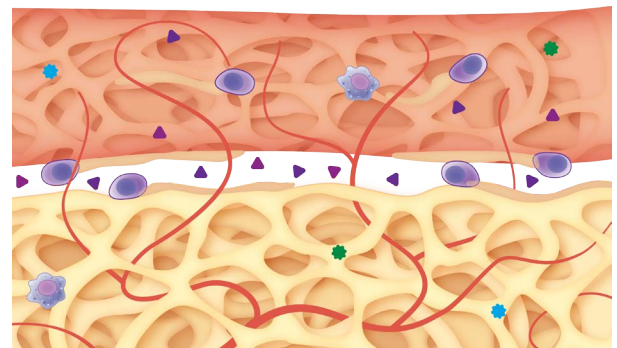
### References

1. Data on file. RPT-000327 Report on Growth Factor Concentrations in Bone and Bone Marrow Aspirate, December 3, 2010, Advanced Biologics, LLC. Data from a single lot of OSTEOAMP sponge product.
2. High levels relative to those reported in published literature for other allografts.
3. Bae H, Zhao L, Zhu D, Kanim L, Wang J, Delamarter R. Variability Across Ten Production Lots of a Single Demineralized Bone Matrix Product. *J BJS*. 2010;92:427-435.
4. Park JJ, Hershman SH, Kim YH. Updates in the Use of Bone Grafts in the Lumbar Spine. *Bulletin of the Hospital for Joint Diseases*. 2013;71(1):39-48.
5. Dimitriou R, Tsirodis E, Giannoudis PV. Current Concepts of Molecular Aspects of Bone Healing. *Injury, Int. J. Care Injured*. 2005; 36:1392—1404.
6. Yeung C, Field J, Roh J. Clinical Validation of Allogeneic Morphogenetic Protein: Donor Interviariability, Terminal Irradiation and Age of Product is not Clinically Relevant. *J Spine*. 2014;3:173.
7. Field J, Yeung C, Roh J. Clinical Evaluation of Allogeneic Growth Factor in Cervical Spine Fusion. *J Spine* 2014;3:158.
8. Roh JS, Yeung CA, Field JS, McClellan RT. Allogeneic morphogenetic protein vs. recombinant human bone morphogenetic protein-2 in lumbar interbody fusion procedures: a radiographic and economic analysis. *J Orthop Surg Res*. 2013;8:49.
9. Data on file. TR-1005 Report on Growth Factor Concentrations in Sponges, Granules and Putty, July 5, 2011, Advanced Biologics, LLC.



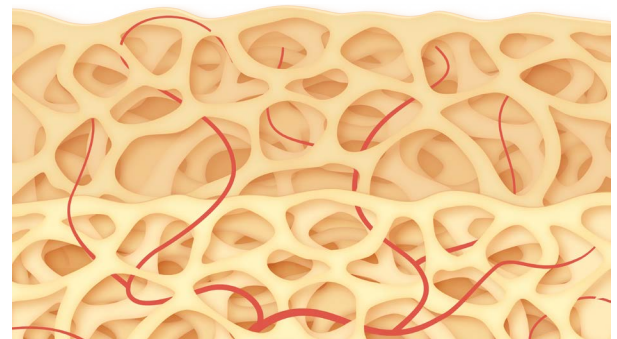
### Step 1

OSTEOAMP, an osteoconductive, osteoinductive, and angiogenic bone graft substitute, is placed at the fusion site.<sup>9</sup> Cells are attracted to the site of injury in response to cytokines and endogenous growth factors in the bone healing environment.



### Step 2

The endogenous osteoinductive and angiogenic growth factors in OSTEOAMP contribute to the bone healing process. Osteoinductive growth factors, such as BMPs, are known to promote cellular recruitment, proliferation and differentiation of bone cells, which promotes bone formation.<sup>5</sup> Angiogenic growth factors initiate development of new vessels. Osteoblasts lay down new osteoid matrix.



### Step 3

OSTEOAMP is incorporated into the site of bone healing. Mineralization of the osteoid matrix occurs, creating solid fusion. This is followed by bone re-modelling where OSTEOAMP is replaced by host bone.

