

## EXOGEN Case Study Report

**DISTAL TIBIAL PILON NONUNION****Physician:** Damien Billow, MD, Assistant Professor of Surgery, Orthopaedic Surgery, Cleveland Clinic**Patient Information:**

Age: 52 years old  
 Sex: Male  
 Weight: 270 lb (BMI 39 kg/m<sup>2</sup>)

**Fracture:**

Closed comminuted distal tibial pilon nonunion  
 (comminution involved all of distal tibial metaphysis and extended into distal tibial diaphysis)

**Outcome:**

Fracture healed with approximately 3 months use of EXOGEN

**Cause of Injury:**

The patient fell from a ladder

**Comorbidities/Risk Factors:**

- Obesity
- Former smoker
- Location of fracture

**Treatment Objectives:**

- Achieve bony healing
- Eliminate the need for additional surgery

**Prior Treatments:**

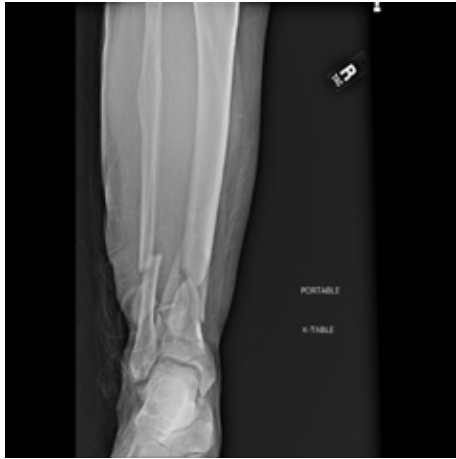- Exfix
- ORIF

**Patient Motivation to Heal:**

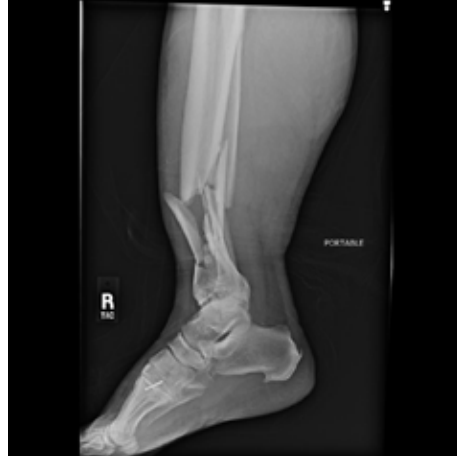- Avoid further surgery

**Treatment Plan:**

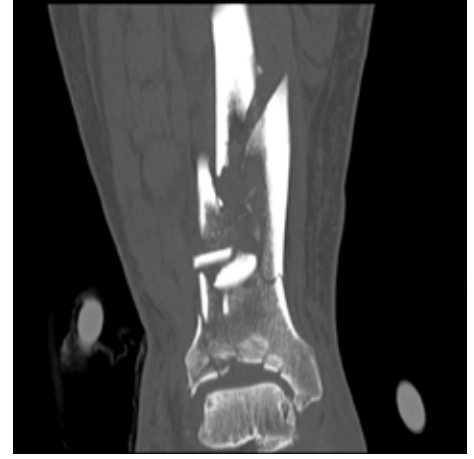
- January 28, 2017: Exfix
- February 13, 2017: ORIF
- Post Op: NWB
- April 5, 2017: No progression of healing shown, EXOGEN prescribed
- May 17, 2017: Advanced to WBAT. X-rays showed some healing and increased density in the zone of fracture
- July 19, 2017: Fracture healed



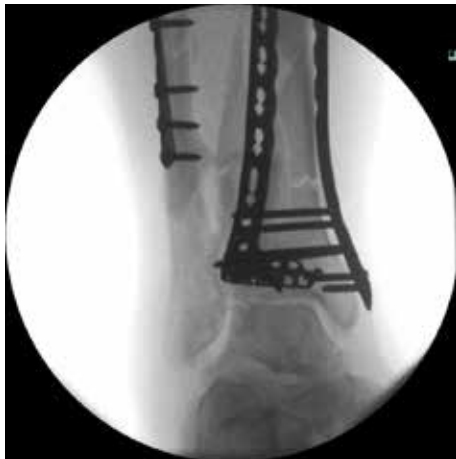January 28, 2017 At Injury AP Ankle



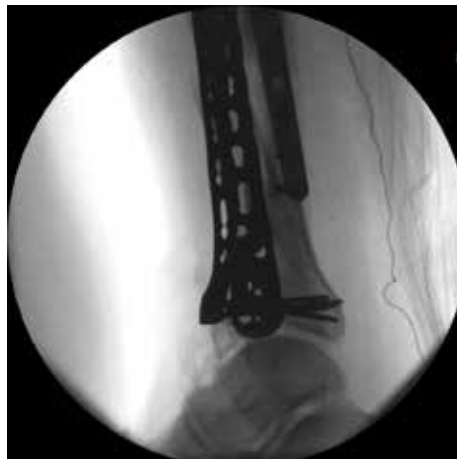January 28, 2017 At Injury Lat Ankle



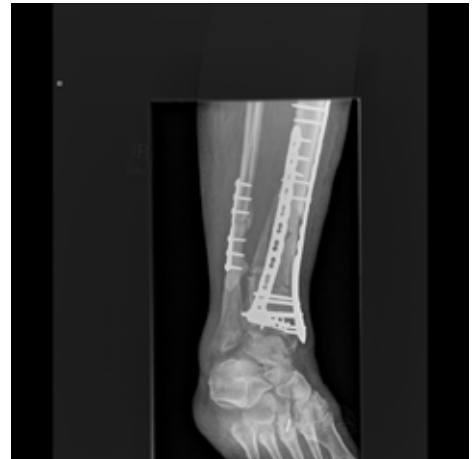February 7, 2017: CT Post Exfix



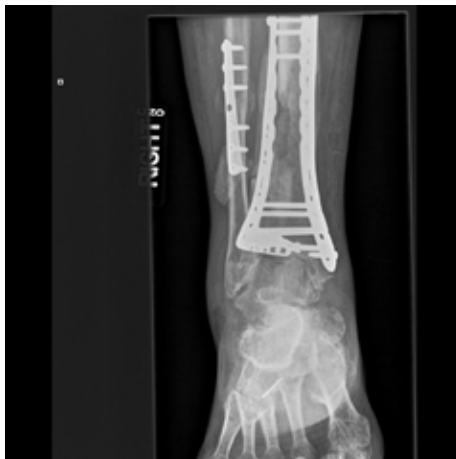February 13, 2017 Fluoro: ORIF Intraop AP1



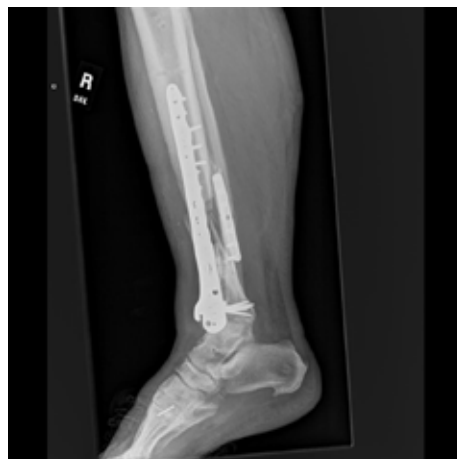February 13, 2017 Fluoro: ORIF Intraop Lat1



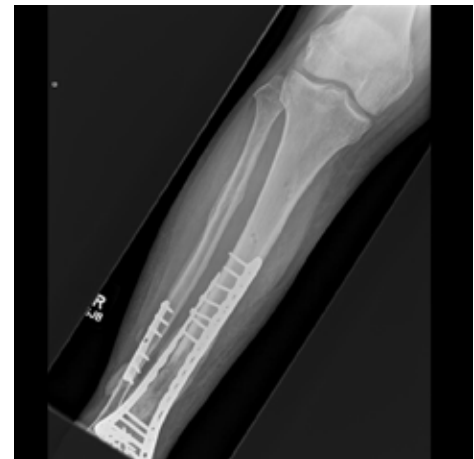April 5, 2017 Post Op: AP Ankle; Initiate EXOGEN Use



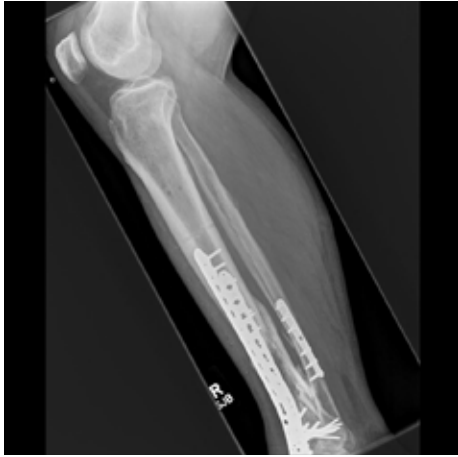April 5, 2017 Post Op: Lat Ankle; Initiate EXOGEN Use



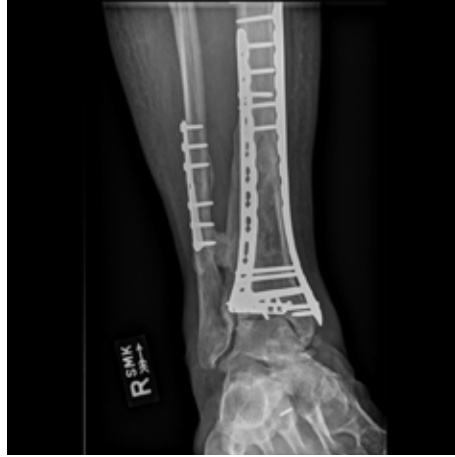April 5, 2017 Post Op: Lat Tibia; Initiate EXOGEN Use



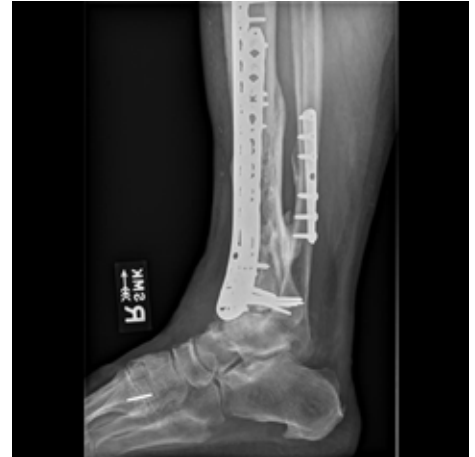July 19, 2017: AP Tibia; ~ 3 Months EXOGEN Use



July 19, 2017: Lat Tibia;  
~ 3 Months EXOGEN Use



January 24, 2018: AP Ankle;  
~ 9 Months EXOGEN Use



January 24, 2018: Lat Ankle;  
~ 9 Months EXOGEN Use

The EXOGEN Ultrasound Bone Healing System is indicated for the non-invasive treatment of established nonunions\* excluding skull and vertebra. In addition, EXOGEN is indicated for accelerating the time to a healed fracture for fresh, closed, posteriorly displaced distal radius fractures and fresh, closed or Grade I open tibial diaphysis fractures in skeletally mature individuals when these fractures are orthopaedically managed by closed reduction and cast immobilization. There are no known contraindications for the EXOGEN device.

Safety and effectiveness have not been established for individuals lacking skeletal maturity, pregnant or nursing women, patients with cardiac pacemakers, on fractures due to bone cancer, or on patients with poor blood circulation or clotting problems. Some patients may be sensitive to the ultrasound gel. Full prescribing information can be found in product labeling, at [www.exogen.com](http://www.exogen.com), or by calling customer service at 1-800-836-4080.

\*A nonunion is considered to be established when the fracture site shows no visibly progressive signs of healing.